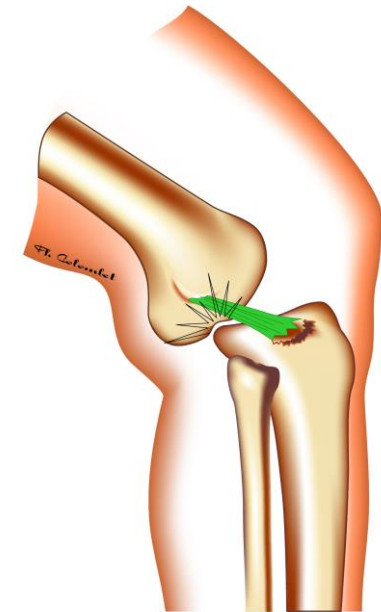



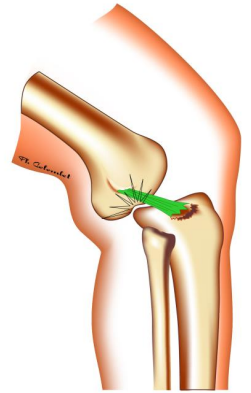


High incidence of ALL Segond avulsion in Ultrasound imaging

Burt Klos
Marlon Scholtes
Stephan Konijnenberg
The Netherlands

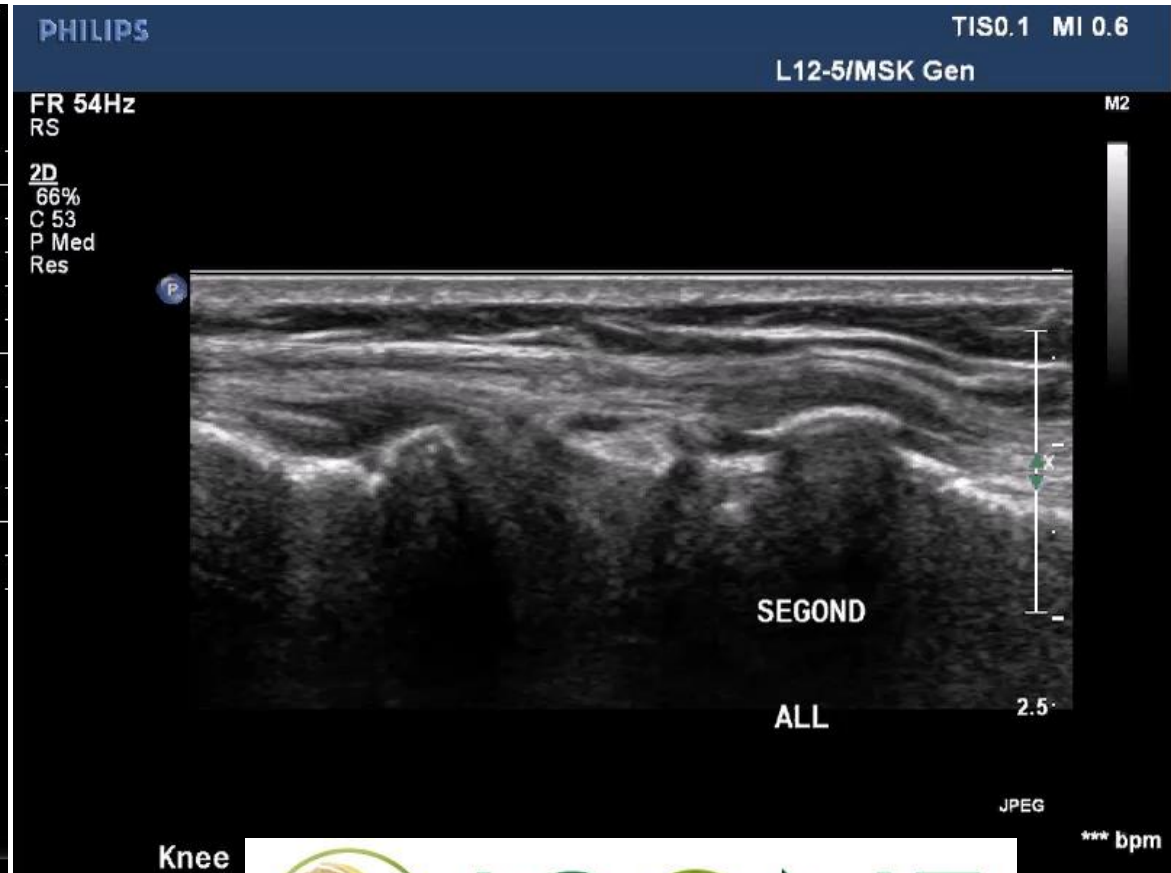
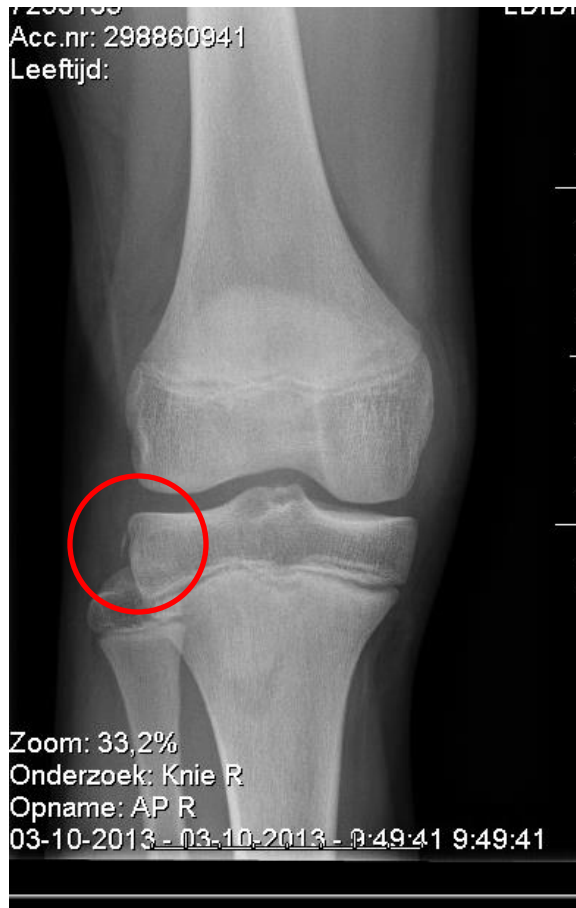
Misunderstanding :

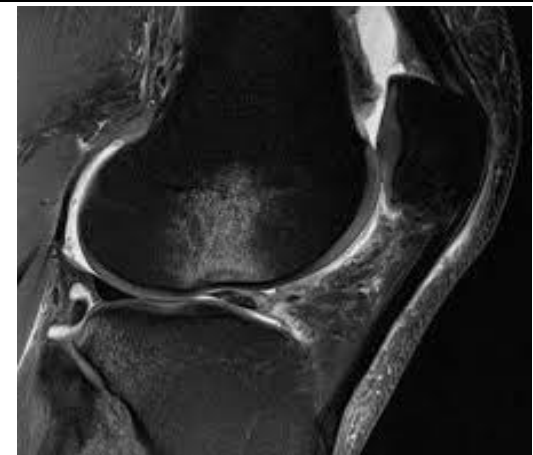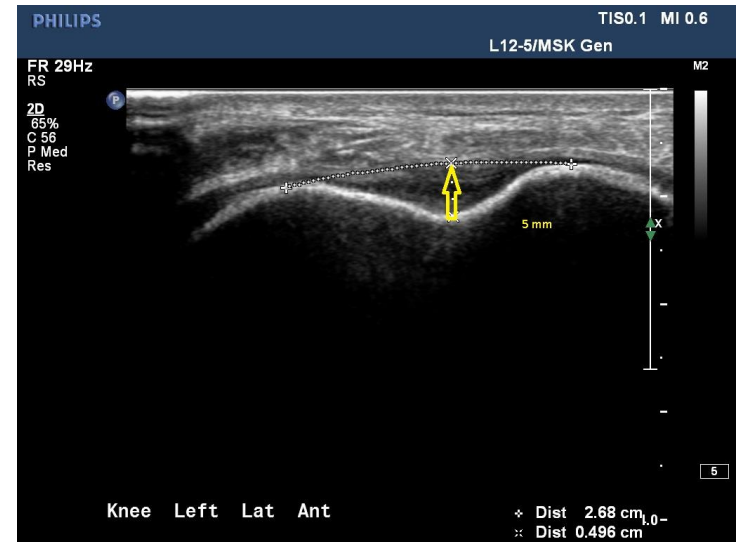
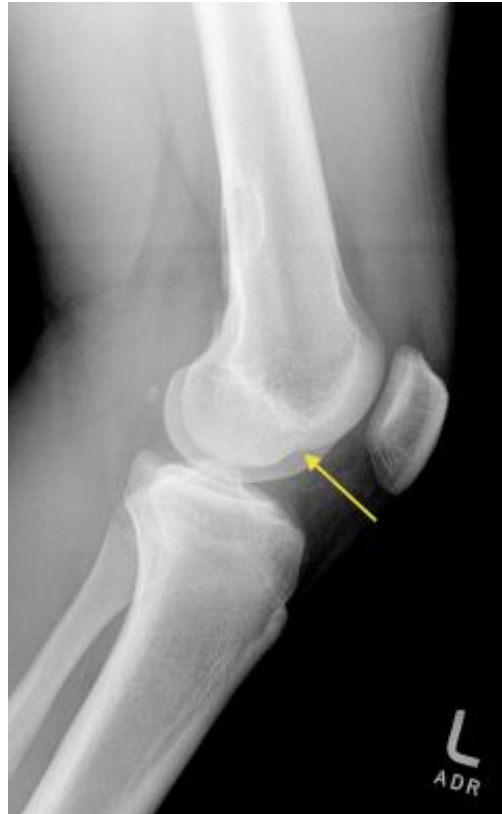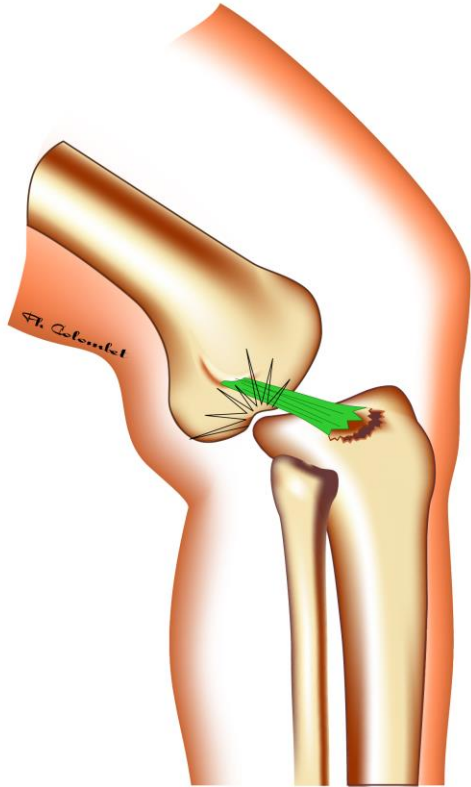


- Segond avulsion is only a minor small fragment (on X ray)
- Segond fracture is not attached to strong ligament complex (not just small ALL)
- Segond fracture is rare (hard to find)
- Segond fracture itself needs no treatment .
- Segond fracture cannot be fixed (with a implant)

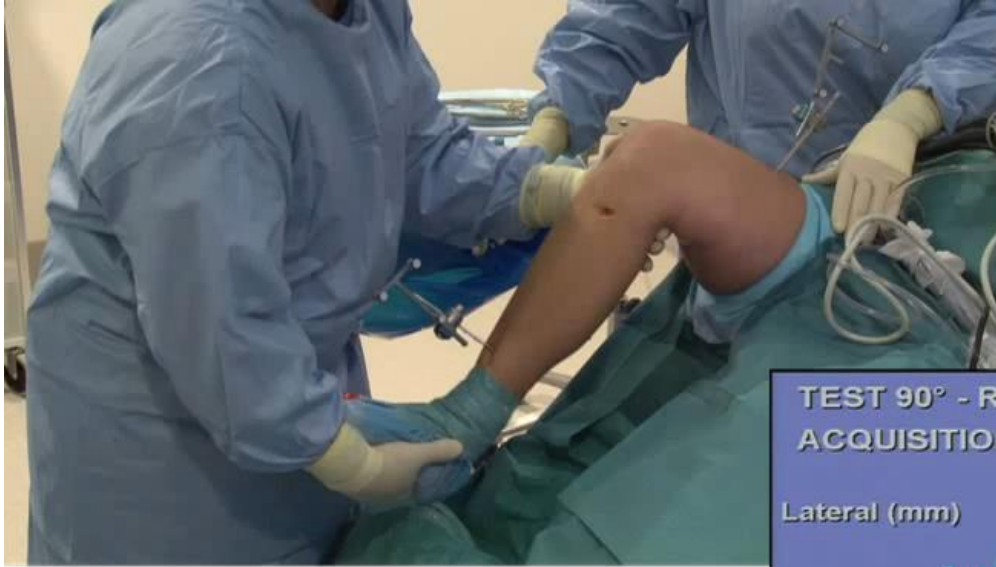Segond fractuur



Primary injury / X ray information



Rotation



TEST 90° - ROTATION ACQUISITION

Lateral (mm)

Ant 0 4 Post 4

Ext 13 13

Ant 2 2 Post 0 2

Medial (mm)

Axial rotation (°)

5 POSITIONS (MIN 10 - MAX 500)
FLEXION: 82° ROTATION: 10° EXT

Perform the rotation test at 90°. BLUE pedal to stop the acquisition.

ACL Surgeries

P T F
1 2 C

PRE-OP. LAXITIES

DRAWER

ROTATION 90°

LACHMAN

ROTATION 30°

VAR.-VALG. STABILITY


PIVOT-SHIFT

PRE-OP. SUMMARY

PRAXIM



ICONE



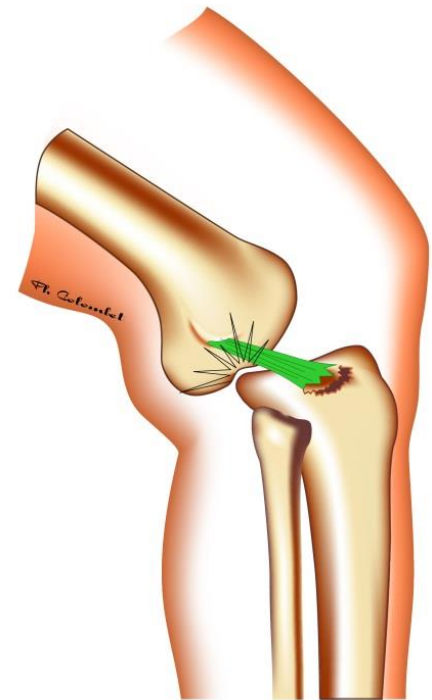
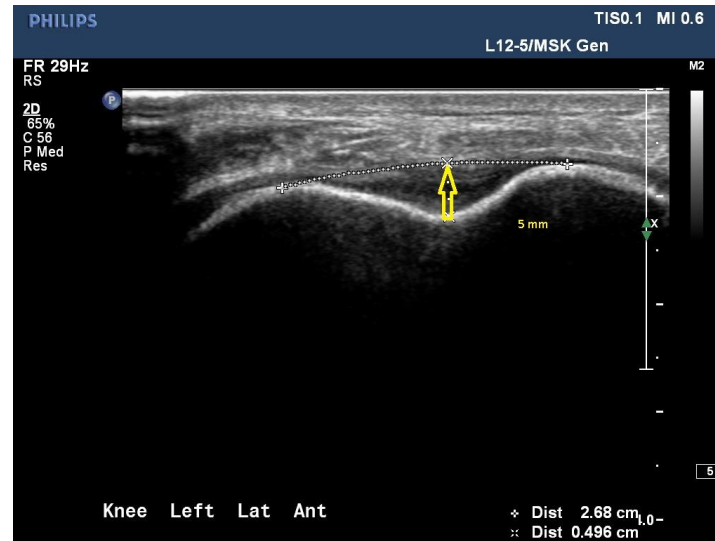
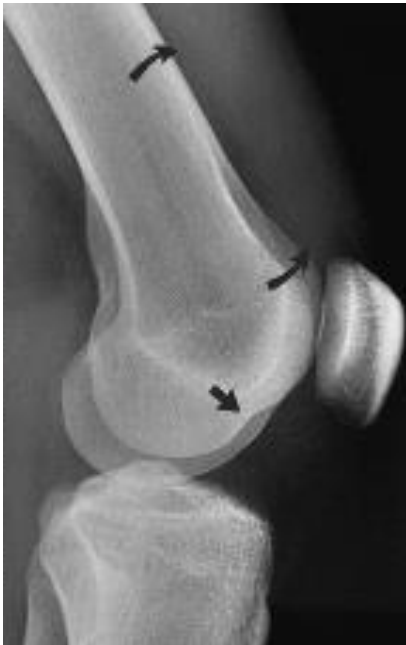KSSTA April 2017

- High prevalence of ALL complex Segond avulsion using ultrasound imaging .
- Klos / Scholtes / Konijnenberg
- Ultrasound should be considered in case of impaction fracture to check for Segond avulsion.



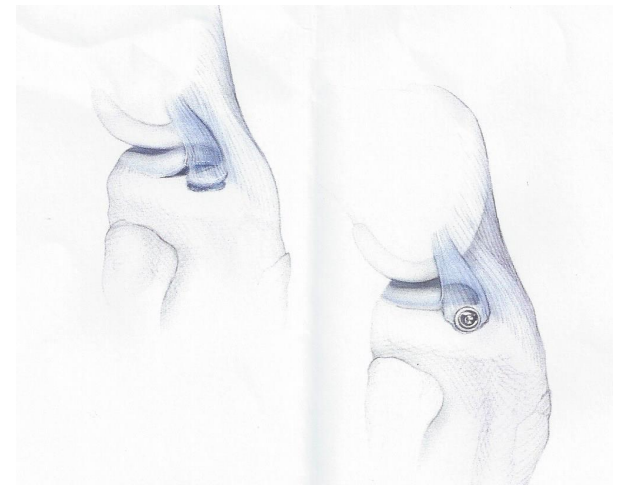
Ultrasound imaging

- 88 patients with ACL #
- 25 Segond lesions (29 %)
- 40 Impaction # lateral FC (46%)

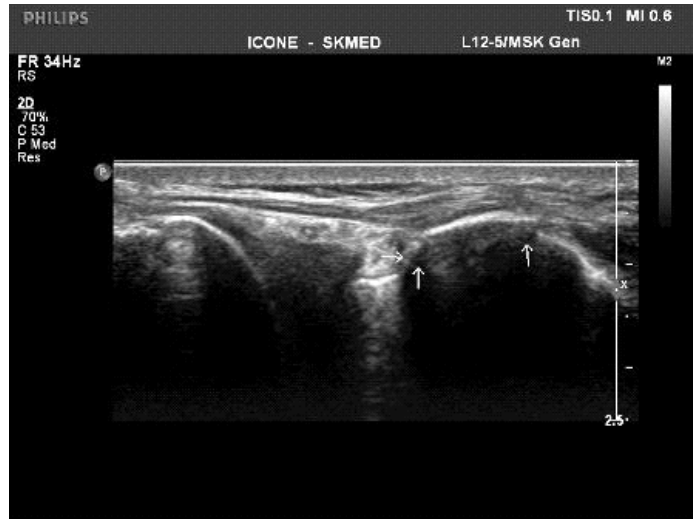

Imaging Segond avulsion

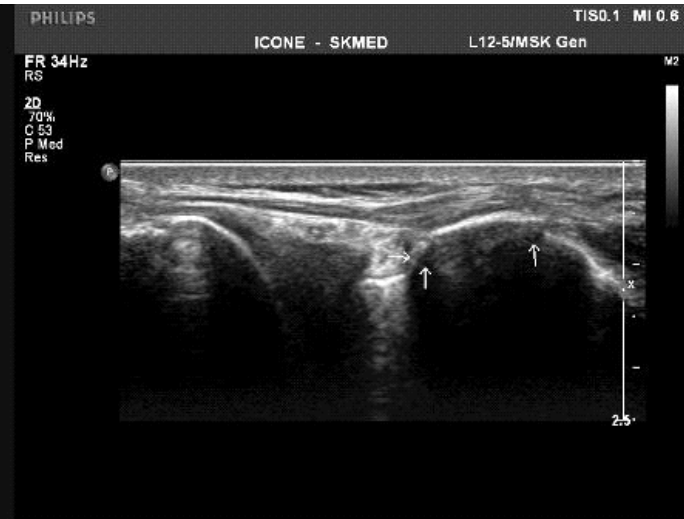- Incidence in MRI 3-6 % Resnick USA
- Incidence in X ray CORR Hess D 9 %
- Incidence ultrasound 29 % (ICONE)
- Refixation / Feagin
- N = 1



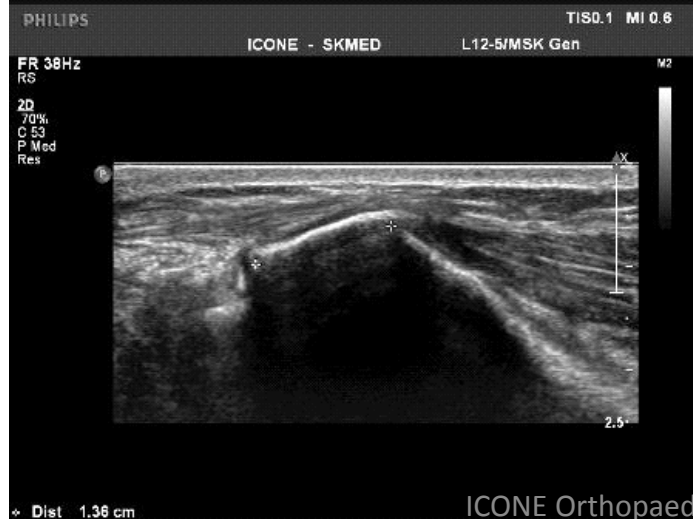US patho anatomy ALL complex



251196WI 34261320140225



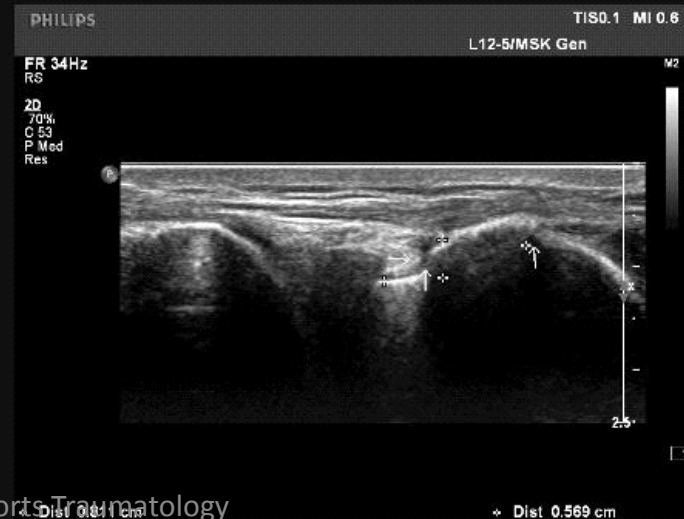251196WI 34261320140225



Dist 1.36 cm

ICONE Orthopaedics & Sports Traumatology

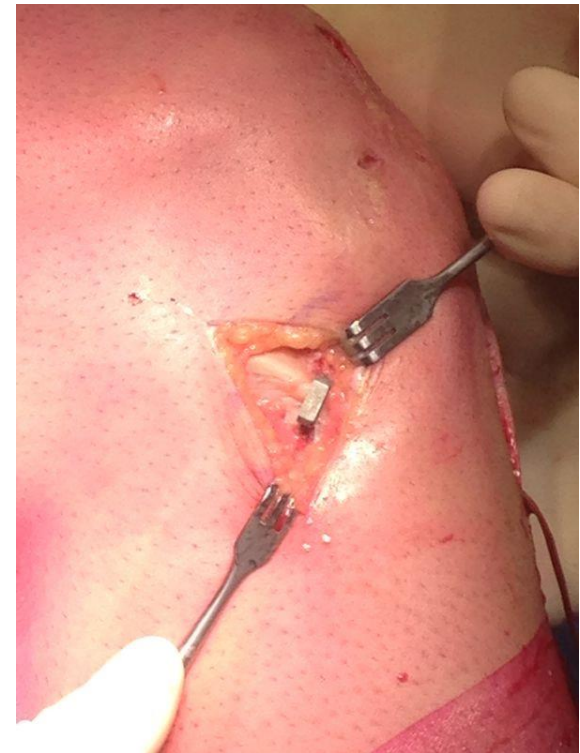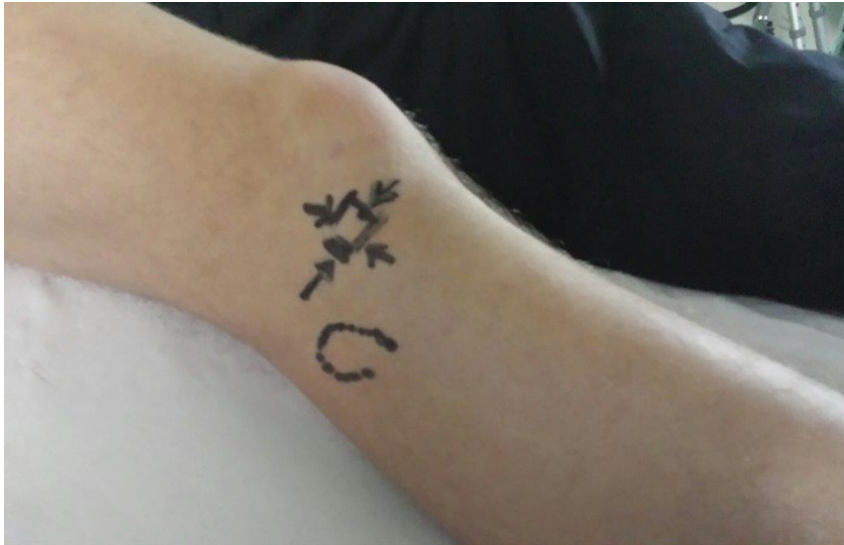251196WI 34261320140225



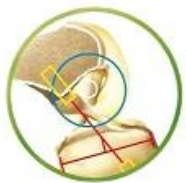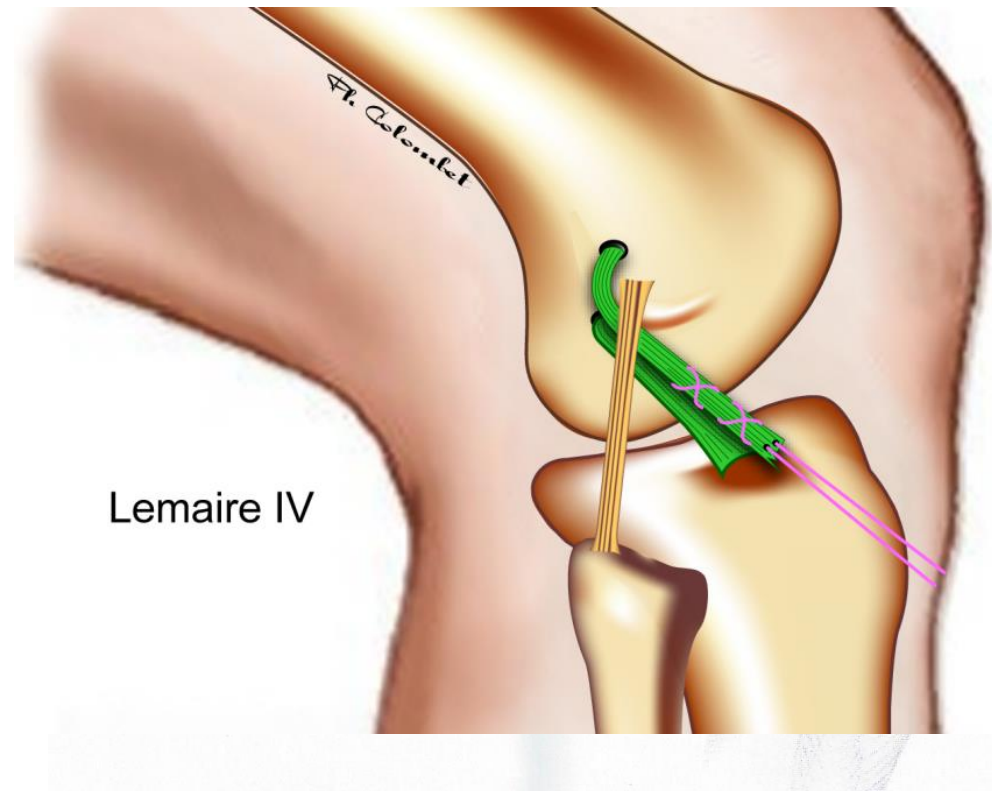
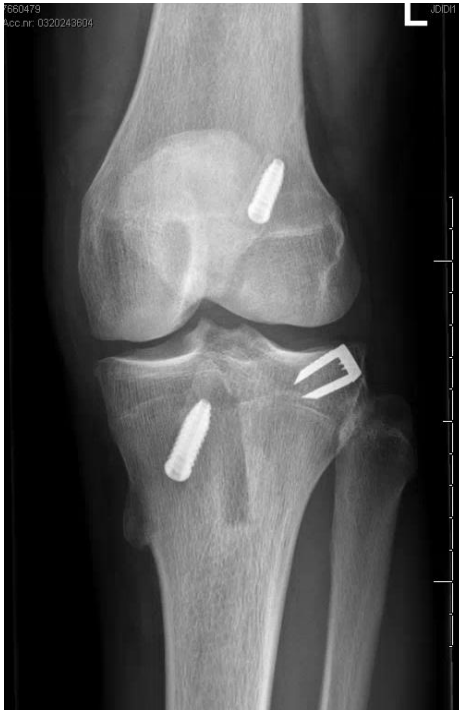Dist 0.569 cm

251196WI 34261320140225

Preoperative marker of Segond avulsion / ultrasound



Refixing Segond or reconstruction AL tenodesis?



ICONE

Discussion ALL lesions location

- Ferretti I : surgical dissection in ACLR :
- Arthroscopy 2016 ALL 54/60 lesions
- Distal lesions 19/60 (32 %)
- Cavaignac F
- Arthroscopy 2017 : Ultrasound Segond avulsion 15/ 30 (50 %) / MRI 4/30 (13 %)



Conclusion

- Segond avulsions are not rare
- Improving diagnosis and treatment
 - Improved Imaging Ultrasound (vs MRI)
 - Segond avulsion is attached to ITB / ALL complex
 - Surgical treatment or neglect /reconstruction ?
 - Fixation method ?

